

50<sup>th</sup> ANNIVERSARY  
EDITION!

Anthony L. Mescher

# JUNQUEIRA'S

## Basic Histology

### TEXT & ATLAS

SIXTEENTH EDITION

Mc  
Graw  
Hill

**LANGGE**<sup>®</sup>

SIXTEENTH EDITION

**Junqueira's**

# Basic Histology

TEXT AND ATLAS

**Anthony L. Mescher, PhD**

Professor of Anatomy and Cell Biology  
Indiana University School of Medicine  
Bloomington, Indiana



New York Chicago San Francisco Athens London Madrid Mexico City  
Milan New Delhi Singapore Sydney Toronto

Copyright © 2021 by McGraw Hill. All rights reserved. Except as permitted under the United States Copyright Act of 1976, no part of this publication may be reproduced or distributed in any form or by any means, or stored in a database or retrieval system, without the prior written permission of the publisher.

ISBN: 978-1-26-046297-5

MHID: 1-26-046297-8

The material in this eBook also appears in the print version of this title: ISBN: 978-1-26-046298-2,  
MHID: 1-26-046298-6.

eBook conversion by codeMantra  
Version 1.0

All trademarks are trademarks of their respective owners. Rather than put a trademark symbol after every occurrence of a trademarked name, we use names in an editorial fashion only, and to the benefit of the trademark owner, with no intention of infringement of the trademark. Where such designations appear in this book, they have been printed with initial caps.

McGraw-Hill Education eBooks are available at special quantity discounts to use as premiums and sales promotions or for use in corporate training programs. To contact a representative, please visit the Contact Us page at [www.mhprofessional.com](http://www.mhprofessional.com).

#### Notice

Medicine is an ever-changing science. As new research and clinical experience broaden our knowledge, changes in treatment and drug therapy are required. The author and the publisher of this work have checked with sources believed to be reliable in their efforts to provide information that is complete and generally in accord with the standards accepted at the time of publication. However, in view of the possibility of human error or changes in medical sciences, neither the author nor the publisher nor any other party who has been involved in the preparation or publication of this work warrants that the information contained herein is in every respect accurate or complete, and they disclaim all responsibility for any errors or omissions or for the results obtained from use of the information contained in this work. Readers are encouraged to confirm the information contained herein with other sources. For example and in particular, readers are advised to check the product information sheet included in the package of each drug they plan to administer to be certain that the information contained in this work is accurate and that changes have not been made in the recommended dose or in the contraindications for administration. This recommendation is of particular importance in connection with new or infrequently used drugs.

#### TERMS OF USE

This is a copyrighted work and McGraw-Hill Education and its licensors reserve all rights in and to the work. Use of this work is subject to these terms. Except as permitted under the Copyright Act of 1976 and the right to store and retrieve one copy of the work, you may not decompile, disassemble, reverse engineer, reproduce, modify, create derivative works based upon, transmit, distribute, disseminate, sell, publish or sublicense the work or any part of it without McGraw-Hill Education's prior consent. You may use the work for your own noncommercial and personal use; any other use of the work is strictly prohibited. Your right to use the work may be terminated if you fail to comply with these terms.

THE WORK IS PROVIDED "AS IS." McGRAW-HILL EDUCATION AND ITS LICENSORS MAKE NO GUARANTEES OR WARRANTIES AS TO THE ACCURACY, ADEQUACY OR COMPLETENESS OF OR RESULTS TO BE OBTAINED FROM USING THE WORK, INCLUDING ANY INFORMATION THAT CAN BE ACCESSED THROUGH THE WORK VIA HYPERLINK OR OTHERWISE, AND EXPRESSLY DISCLAIM ANY WARRANTY, EXPRESS OR IMPLIED, INCLUDING BUT NOT LIMITED TO IMPLIED WARRANTIES OF MERCHANTABILITY OR FITNESS FOR A PARTICULAR PURPOSE. McGraw-Hill Education and its licensors do not warrant or guarantee that the functions contained in the work will meet your requirements or that its operation will be uninterrupted or error free. Neither McGraw-Hill Education nor its licensors shall be liable to you or anyone else for any inaccuracy, error or omission, regardless of cause, in the work or for any damages resulting therefrom. McGraw-Hill Education has no responsibility for the content of any information accessed through the work. Under no circumstances shall McGraw-Hill Education and/or its licensors be liable for any indirect, incidental, special, punitive, consequential or similar damages that result from the use of or inability to use the work, even if any of them has been advised of the possibility of such damages. This limitation of liability shall apply to any claim or cause whatsoever whether such claim or cause arises in contract, tort or otherwise.

# Contents

PREFACE VII | ACKNOWLEDGMENTS IX

## 1 Histology & Its Methods of Study 1

Preparation of Tissues for Study 1  
Light Microscopy 4  
Electron Microscopy 8  
Autoradiography 9  
Cell & Tissue Culture 10  
Enzyme Histochemistry 10  
Visualizing Specific Molecules 10  
Interpretation of Structures in Tissue Sections 14  
Summary of Key Points 15  
Assess Your Knowledge 16

## 2 The Cytoplasm 17

Cell Differentiation 17  
The Plasma Membrane 17  
Cytoplasmic Organelles 27  
The Cytoskeleton 42  
Inclusions 48  
Summary of Key Points 51  
Assess Your Knowledge 52

## 3 The Nucleus 53

Components of the Nucleus 53  
The Cell Cycle 58  
Mitosis 61  
Stem Cells & Tissue Renewal 65  
Meiosis 65  
Apoptosis 67  
Summary of Key Points 69  
Assess Your Knowledge 70

## 4 Epithelial Tissue 71

Characteristic Features of Epithelial Cells 72  
Specializations of the Apical Cell Surface 77  
Types of Epithelia 80  
Transport Across Epithelia 88  
Renewal of Epithelial Cells 88  
Summary of Key Points 90  
Assess Your Knowledge 93

## 5 Connective Tissue 96

Cells of Connective Tissue 96  
Fibers 103  
Ground Substance 111  
Types of Connective Tissue 114  
Summary of Key Points 119  
Assess Your Knowledge 120

## 6 Adipose Tissue 122

White Adipose Tissue 122  
Brown Adipose Tissue 126  
Summary of Key Points 127  
Assess Your Knowledge 128

## 7 Cartilage 129

Hyaline Cartilage 129  
Elastic Cartilage 133  
Fibrocartilage 134  
Cartilage Formation, Growth, & Repair 134  
Summary of Key Points 136  
Assess Your Knowledge 136

## 8 Bone 138

Bone Cells 138  
Bone Matrix 143  
Periosteum & Endosteum 143  
Types of Bone 143  
Osteogenesis 148  
Bone Remodeling & Repair 152  
Metabolic Role of Bone 153  
Joints 155  
Summary of Key Points 158  
Assess Your Knowledge 159

## 9 Nerve Tissue & the Nervous System 161

Development of Nerve Tissue 161  
Neurons 163  
Glial Cells & Neuronal Activity 168  
Central Nervous System 175  
Peripheral Nervous System 182

Neural Plasticity & Regeneration 187  
Summary of Key Points 190  
Assess Your Knowledge 191

## 10 Muscle Tissue 193

Skeletal Muscle 193  
Cardiac Muscle 206  
Smooth Muscle 208  
Regeneration of Muscle Tissue 213  
Summary of Key Points 213  
Assess Your Knowledge 214

## 11 The Circulatory System 215

Heart 215  
Tissues of the Vascular Wall 219  
Vasculature 220  
Lymphatic Vascular System 232  
Summary of Key Points 235  
Assess Your Knowledge 235

## 12 Blood 237

Composition of Plasma 237  
Blood Cells 239  
Summary of Key Points 252  
Assess Your Knowledge 253

## 13 Hemopoiesis 254

Stem Cells, Growth Factors, & Differentiation 254  
Bone Marrow 255  
Maturation of Erythrocytes 258  
Maturation of Granulocytes 260  
Maturation of Agranulocytes 263  
Origin of Platelets 263  
Summary of Key Points 265  
Assess Your Knowledge 265

## 14 The Immune System & Lymphoid Organs 267

Innate & Adaptive Immunity 267  
Cytokines 269  
Antigens & Antibodies 269  
Antigen Presentation 271  
Cells of Adaptive Immunity 273  
Thymus 276  
Mucosa-Associated Lymphoid Tissue 281  
Lymph Nodes 282  
Spleen 286  
Summary of Key Points 293  
Assess Your Knowledge 294

## 15 Digestive Tract 295

General Structure of the Digestive Tract 295  
Oral Cavity 298  
Esophagus 305  
Stomach 307  
Small Intestine 314  
Large Intestine 318  
Summary of Key Points 326  
Assess Your Knowledge 327

## 16 Organs Associated with the Digestive Tract 329

Salivary Glands 329  
Pancreas 332  
Liver 335  
Biliary Tract & Gallbladder 345  
Summary of Key Points 346  
Assess Your Knowledge 348

## 17 The Respiratory System 349

Nasal Cavities 349  
Pharynx 351  
Larynx 352  
Trachea 354  
Bronchial Tree & Lung 354  
Lung Vasculature & Nerves 367  
Pleural Membranes 368  
Respiratory Movements 369  
Summary of Key Points 369  
Assess Your Knowledge 370

## 18 Skin 371

Epidermis 372  
Dermis 380  
Subcutaneous Tissue 381  
Sensory Receptors 382  
Hair 383  
Nails 384  
Skin Glands 385  
Skin Repair 388  
Summary of Key Points 391  
Assess Your Knowledge 392

## 19 The Urinary System 393

Kidneys 393  
Blood Circulation 394  
Renal Function: Filtration, Secretion, & Reabsorption 395  
Ureters, Bladder, & Urethra 406

Summary of Key Points 410  
Assess Your Knowledge 411

## **20 Endocrine Glands 413**

Pituitary Gland (Hypophysis) 413  
Adrenal Glands 423  
Pancreatic Islets 427  
Diffuse Neuroendocrine  
System 429  
Thyroid Gland 430  
Parathyroid Glands 432  
Pineal Gland 435  
Summary of Key Points 437  
Assess Your Knowledge 437

## **21 The Male Reproductive System 439**

Testes 439  
Intratesticular Ducts 449  
Excretory Genital Ducts 449  
Accessory Glands 451  
Penis 456  
Summary of Key Points 457  
Assess Your Knowledge 459

## **22 The Female Reproductive System 460**

Ovaries 460  
Uterine Tubes 470  
Major Events of Fertilization 471  
Uterus 471  
Embryonic Implantation, Decidua, & The Placenta 478  
Cervix 482  
Vagina 483  
External Genitalia 483  
Mammary Glands 483  
Summary of Key Points 488  
Assess Your Knowledge 489

## **23 The Eye & Ear: Special Sense Organs 490**

Eyes: The Photoreceptor System 490  
Ears: The Vestibuloauditory System 509  
Summary of Key Points 522  
Assess Your Knowledge 522

**APPENDIX 525**

**FIGURE CREDITS 527**

**INDEX 529**



# Preface

Publication of the 16th English edition of *Basic Histology* marks the 50th anniversary of the book's creation by L. C. Junqueira, M.D. and colleagues. That edition, the first histology textbook published in soft cover, was compact, concise, highly readable, yet authoritative and quickly set the standard by which subsequent textbooks in the area of histology and cell biology would be judged. After Dr. Junqueira's death I accepted the McGraw Hill editors' challenge to maintain this high standard with the English edition and strove to improve all aspects of the book's utility for the modern student in the health professions while maintaining its compact size and ease of use. Based on its position as a perennial best-seller among Histology textbooks on Amazon and its selection as a Core Title in the Health Sciences by Doody's Book Review Service, *Junqueira's Basic Histology* clearly continues as the preeminent source of **concise yet thorough** information on human tissue structure and function. For five decades this educational resource has met the needs of learners for a well-organized and summarizing presentation of **cell biology and histology** that integrates the material with that of **biochemistry, immunology, endocrinology, and physiology** and provides an excellent foundation for subsequent studies in **pathology**. The text is prepared specifically for students of medicine and other health-related professions, as well as for advanced undergraduate courses in human tissue biology. Because of its value and appeal to students and instructors alike, *Junqueira's Basic Histology: Text and Atlas* has been translated into **more than a dozen languages** and is used in medical schools throughout the world.

Unlike any other histology texts and atlases, each chapter of this edition again includes a set of multiple-choice **Self-Test Questions**, which allow readers to assess their comprehension and knowledge of important points in the subject. A few questions in each set utilize clinical vignettes for framing the medical relevance and applications of basic science concepts, as recommended by the United States National Board of Medical Examiners, in addition to the questions assessing learners' understanding of basic concepts. Each chapter also includes a **Summary of Key Points** to guide students for review of the most clearly important information. **Summary Tables** in each chapter organize and condense important information, facilitating efficient learning. Modern page design and graphics further simplify study of this material.

Each chapter has been revised and shortened where feasible, while coverage of specific topics has been expanded and

updated as needed. Inserted throughout each chapter are more numerous, short paragraphs indicating how the information presented can be applied clinically and emphasizing the foundational relevance of the material learned.

The art and other figures are presented in each chapter, with the goal to simplify learning and integration with related material. Used throughout the text the McGraw Hill biomedical illustrations are arguably the most useful, thorough, and attractive of any similar medical textbook. Every human tissue and cell is shown with electron and light micrographs which comprise a complete atlas of cell, tissue, and organ structures fully compatible with the students' own collection of glass or digital light microscope slides.

The digital version of *Junqueira's Basic Histology: Text and Atlas* includes significant changes with this edition. The digital version is available at no charge to health science students whose medical library offers McGraw Hill's **AccessMedicine** among its electronic resources, which includes the library resources of more than 95% of medical schools in North America. Each chapter of this new SIXTEENTH edition now incorporates a detailed **Lab Guide** for that material, including (1) **the learning objectives for that laboratory session**, (2) **a list of important structures to identify and terms to use and understand**, (3) **detailed microscopic directions for studying each tissue and locating those structures**, and (4) **self-assessment questions** with each session. These laboratory exercises link the photographic material in the Junqueira textbook and correlate with slides in any virtual or glass slide collection, making this digital Lab Guide a unique instrument among the learning resources of any other histology text and atlas. **No other major textbook of tissue biology includes such detailed guidance for learners through the microscopic or laboratory portion of the typical medical school coverage of histology.** As of this writing in mid-2020, the previous FIFTEENTH edition of Junqueira on AccessMedicine continues to include these features of the digital Lab Guide, along with links to an excellent collection of scannable and focusable virtual light microscope slides.

Students who cannot link to AccessMedicine will lack this digital Lab Guide but may still utilize the collection of over 150 virtual light microscope slides of human tissues and organs at: <http://medsci.indiana.edu/junqueira/virtual/junqueira.htm>. This set of virtual slides is presently available without restrictions for use with any instructor's guide for human histology lab exercises.



As with other recent editions of *Junqueira*, both print and digital versions of this edition facilitate learning by their overall **organization**:

- An opening chapter reviews the **histological techniques** which allow understanding of cell and tissue structure.
- Two chapters then summarize the structural and functional organization of **human cell biology**, presenting the cytoplasm and nucleus separately.
- The next seven chapters cover the **four basic tissues** that make up our organs: epithelia, connective tissue (and its major sub-types), nervous tissue, and muscle.
- Remaining chapters explain the organization and functional significance of these tissues in **each of the body's organ systems**, closing with up-to-date consideration of cells in the unique organs of special sense, the eye and ear.

For additional review of what's been learned or to assist rapid assimilation of the material in *Junqueira's Basic Histology*, McGraw Hill has published a set of 200 full-color **Basic Histology Flash Cards**, which I've also authored. Each card includes images of key structures to identify, a summary of important facts about those structures, and a clinical comment. This valuable learning aid is available as a set of actual cards from Amazon.com, or as an app for smartphones or tablets from the online App Store.

With its proven strengths, excellent up-to-date pedagogical features, and links with the new digital Lab Guide, I am confident that *Junqueira's Basic Histology* will continue as one of the most valuable and most widely read educational resources in histology. As always, users are invited to provide me with feedback about any aspect of the book's content or features.

**Anthony L. Mescher**  
**Indiana University School of Medicine—Bloomington**

# Acknowledgments

I wish to thank the students at Indiana University School of Medicine and the undergraduates at Indiana University Bloomington with whom I studied histology and cell biology for over 38 years and from whom I have learned much about presenting basic concepts most effectively. Their input has greatly helped in the task of maintaining and updating the presentations in this classic textbook. The help of Sue Childress and Dr. Mark Braun was invaluable in slide preparation and creation of the virtual microscope for human histology respectively.

As with the last edition, the present text includes multiple-choice questions at the end of each chapter, aimed to test the learner's retention and understanding of important points in that body of material. Many of these questions were used in my courses, but others are taken or modified from a few of the many excellent review books published by McGraw Hill/Lange for students preparing to take the United States Medical Licensing Examination. These include *Histology and Cell Biology: Examination and Board Review*, by Douglas Paulsen; *USMLE Road Map: Histology*, by Harold Sheedlo; and

*Anatomy, Histology, & Cell Biology: PreTest Self-Assessment & Review*, by Robert Klein and George Enders. The use here of questions from these valuable resources is gratefully acknowledged. Students are referred to those review books for hundreds of additional self-assessment questions.

I am also grateful to colleagues and reviewers throughout the world who provided specialized expertise or original photographs, as also acknowledged further in these figures' captions. I thank those professors and students in the United States and countries throughout the world who provided useful suggestions that have improved the new edition of *Junqueira's Basic Histology*. Finally, I am pleased to acknowledge the help and collegiality provided by the staff of McGraw Hill, especially editor Michael Weitz, whose work made possible publication of this 16th edition of *Junqueira's Basic Histology: Text and Atlas*.

**Anthony L. Mescher**  
**Indiana University School of Medicine—Bloomington**



# Histology & Its Methods of Study

<b>PREPARATION OF TISSUES FOR STUDY</b>	<b>1</b>	<b>AUTORADIOGRAPHY</b>	<b>9</b>
Fixation	1	<b>CELL &amp; TISSUE CULTURE</b>	<b>10</b>
Embedding & Sectioning	3	<b>ENZYME HISTOCHEMISTRY</b>	<b>10</b>
Staining	3	<b>VISUALIZING SPECIFIC MOLECULES</b>	<b>10</b>
<b>LIGHT MICROSCOPY</b>	<b>4</b>	Immunohistochemistry	11
Bright-Field Microscopy	4	Hybridization Techniques	12
Fluorescence Microscopy	5	<b>INTERPRETATION OF STRUCTURES IN TISSUE SECTIONS</b>	<b>14</b>
Phase-Contrast Microscopy	5	<b>SUMMARY OF KEY POINTS</b>	<b>15</b>
Confocal Microscopy	5	<b>ASSESS YOUR KNOWLEDGE</b>	<b>16</b>
Polarizing Microscopy	7		
<b>ELECTRON MICROSCOPY</b>	<b>8</b>		
Transmission Electron Microscopy	8		
Scanning Electron Microscopy	9		

**H**istology is the study of the tissues of the body and how these tissues are arranged to constitute organs. This subject involves all aspects of tissue biology, with the focus on how cells' structure and arrangement optimize functions specific to each organ.

Tissues have two interacting components: cells and extracellular matrix (ECM). The ECM consists of many kinds of macromolecules, most of which form complex structures, such as collagen fibrils. The ECM supports the cells and contains the fluid transporting nutrients to the cells, and carrying away their wastes and secretory products. Cells produce the ECM locally and are in turn strongly influenced by matrix molecules. Many matrix components bind to specific cell surface receptors that span the cell membranes and connect to structural components inside the cells, forming a continuum in which cells and the ECM function together in a well-coordinated manner.

During development, cells and their associated matrix become functionally specialized and give rise to fundamental types of tissues with characteristic structural features. Organs are formed by an orderly combination of these tissues, and their precise arrangement allows the functioning of each organ and of the organism as a whole.

The small size of cells and matrix components makes histology dependent on the use of microscopes and molecular methods of study. Advances in biochemistry, molecular biology, physiology, immunology, and pathology are essential for

a better knowledge of tissue biology. Familiarity with the tools and methods of any branch of science is essential for a proper understanding of the subject. This chapter reviews common methods used to study cells and tissues, focusing on microscopic approaches.

## ► PREPARATION OF TISSUES FOR STUDY

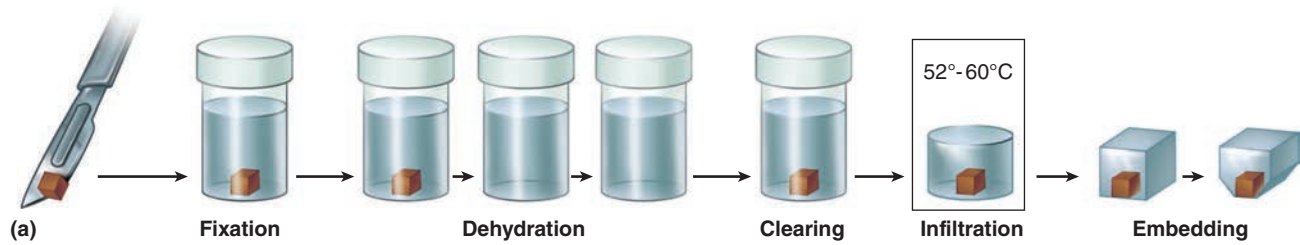
The most common procedure used in histologic research is the preparation of tissue slices or “sections” that can be examined visually with transmitted light. Because most tissues and organs are too thick for light to pass through, thin translucent sections are cut from them and placed on glass slides for microscopic examination of the internal structures.

The ideal microscopic preparation is preserved so that the tissue on the slide has the same structural features it had in the body. However, this is often not feasible because the preparation process can remove cellular lipid, with slight distortions of cell structure. The basic steps used in tissue preparation for light microscopy are shown in Figure 1–1.

### Fixation

To preserve tissue structure and prevent degradation by enzymes released from the cells or microorganisms, pieces of

FIGURE 1–1 Sectioning fixed and embedded tissue.



Most tissues studied histologically are prepared as shown, with this sequence of steps (a):

- **Fixation:** Small pieces of tissue are placed in solutions of chemicals that cross-link proteins and inactivate degradative enzymes, which preserve cell and tissue structure.
- **Dehydration:** The tissue is transferred through a series of increasingly concentrated alcohol solutions, ending in 100%, which removes all water.
- **Clearing:** Alcohol is removed in organic solvents in which both alcohol and paraffin are miscible.
- **Infiltration:** The tissue is then placed in melted paraffin until it becomes completely infiltrated with this substance.
- **Embedding:** The paraffin-infiltrated tissue is placed in a small mold with melted paraffin and allowed to harden.
- **Trimming:** The resulting paraffin block is trimmed to expose the tissue for sectioning (slicing) on a microtome.

Similar steps are used in preparing tissue for transmission electron microscopy (TEM), except special fixatives and dehydrating solutions are used with smaller tissue samples and embedding involves epoxy resins which become harder than paraffin to allow very thin sectioning.

(b) A **microtome** is used for sectioning paraffin-embedded tissues for light microscopy. The trimmed tissue specimen is mounted in the paraffin block holder, and each turn of the drive wheel by the histologist advances the holder a controlled distance, generally from 1 to 10  $\mu\text{m}$ . After each forward move, the tissue block passes over the steel knife edge and a section is cut at a thickness equal to the distance the block advanced. The paraffin sections are placed on glass slides and allowed to adhere, deparaffinized, and stained for light microscope study. For TEM, sections less than 1  $\mu\text{m}$  thick are prepared from resin-embedded cells using an ultramicrotome with a glass or diamond knife.

organs are placed as soon as possible after removal from the body in solutions of stabilizing or cross-linking compounds called **fixatives**. Because a fixative must fully diffuse through the tissues to preserve all cells, tissues are usually cut into small fragments before fixation to facilitate penetration. To improve cell preservation in large organs, fixatives are often introduced via blood vessels, with vascular perfusion allowing fixation rapidly throughout the tissues.

One widely used fixative for light microscopy is formalin, a buffered isotonic solution of 37% formaldehyde. Both this compound and glutaraldehyde, a fixative used for electron

microscopy, react with the amine groups ( $\text{NH}_2$ ) of proteins, preventing their degradation by common proteases. Glutaraldehyde also cross-links adjacent proteins, reinforcing cell and ECM structures.

Electron microscopy provides much greater magnification and resolution of very small cellular structures, and fixation must be done very carefully to preserve additional “ultrastructural” detail. Typically in such studies, glutaraldehyde-treated tissue is then immersed in buffered osmium tetroxide, which preserves (and stains) cellular lipids as well as proteins.

## Embedding & Sectioning

To permit thin sectioning, fixed tissues are infiltrated and embedded in a material that imparts a firm consistency. Embedding materials include paraffin, used routinely for light microscopy, and plastic resins, which are adapted for both light and electron microscopy.

Before infiltration with such media, the fixed tissue must undergo **dehydration** by having its water extracted gradually by transfers through a series of increasing ethanol solutions, ending in 100% ethanol. The ethanol is then replaced by an organic solvent miscible with both alcohol and the embedding medium, a step referred to as **clearing** because infiltration with the reagents used here gives the tissue a translucent appearance.

The fully cleared tissue is then placed in melted paraffin in an oven at 52°C–60°C, which evaporates the clearing solvent and promotes **infiltration** of the tissue with paraffin, and then **embedded** by allowing it to harden in a small container of paraffin at room temperature. Tissues to be embedded with plastic resin are also dehydrated in ethanol and then infiltrated with plastic solvents that harden when cross-linking polymerizers are added. Plastic embedding avoids the higher temperatures needed with paraffin, which helps avoid tissue distortion.

The hardened block with tissue and surrounding embedding medium is trimmed and placed for sectioning in an instrument called a **microtome** (Figure 1–1). Paraffin sections are typically cut at 3–10  $\mu\text{m}$  thickness for light microscopy, but electron microscopy requires sections less than 1  $\mu\text{m}$  thick. One micrometer (1  $\mu\text{m}$ ) equals 1/1000 of a millimeter (mm) or  $10^{-6}$  m. Other spatial units commonly used in microscopy are the nanometer (1 nm = 0.001  $\mu\text{m}$  =  $10^{-6}$  mm =  $10^{-9}$  m) and angstrom (1  $\text{\AA}$  = 0.1 nm or  $10^{-4}$   $\mu\text{m}$ ). The sections are placed on glass slides and stained for light microscopy or on metal grids for electron-microscopic staining and examination.

### »» MEDICAL APPLICATION

Biopsies are tissue samples removed during surgery or routine medical procedures. In the operating room, biopsies are fixed in vials of formalin for processing and microscopic analysis in a pathology laboratory. If results of such analyses are required before the medical procedure is completed, for example to know whether a growth is malignant before the patient is closed, a much more rapid processing method is used. The biopsy is rapidly frozen in liquid nitrogen, preserving cell structures and at the same time making the tissue hard and ready for sectioning. A microtome called a **cryostat** in a cabinet at subfreezing temperature is used to section the block with tissue, and the frozen sections are placed on slides for rapid staining and microscopic examination by a pathologist.

Freezing of tissues is also effective in histochemical studies of very sensitive enzymes or small molecules because freezing, unlike fixation, does not inactivate most enzymes. Finally, because clearing solvents often dissolve cell lipids in fixed tissues, frozen sections are also useful when structures containing lipids are to be studied histologically.

## Staining

Most cells and extracellular material are completely colorless, and to be studied microscopically tissue sections must be stained (dyed). Methods of staining have been devised that make various tissue components not only conspicuous but also distinguishable from one another. Dyes stain material more or less selectively, often behaving like acidic or basic compounds and forming electrostatic (salt) linkages with ionizable radicals of macromolecules in tissues. Cell components, such as nucleic acids with a net negative charge (anionic), have an affinity for basic dyes and are termed **basophilic**; cationic components, such as proteins with many ionized amino groups, stain more readily with acidic dyes and are termed **acidophilic**.

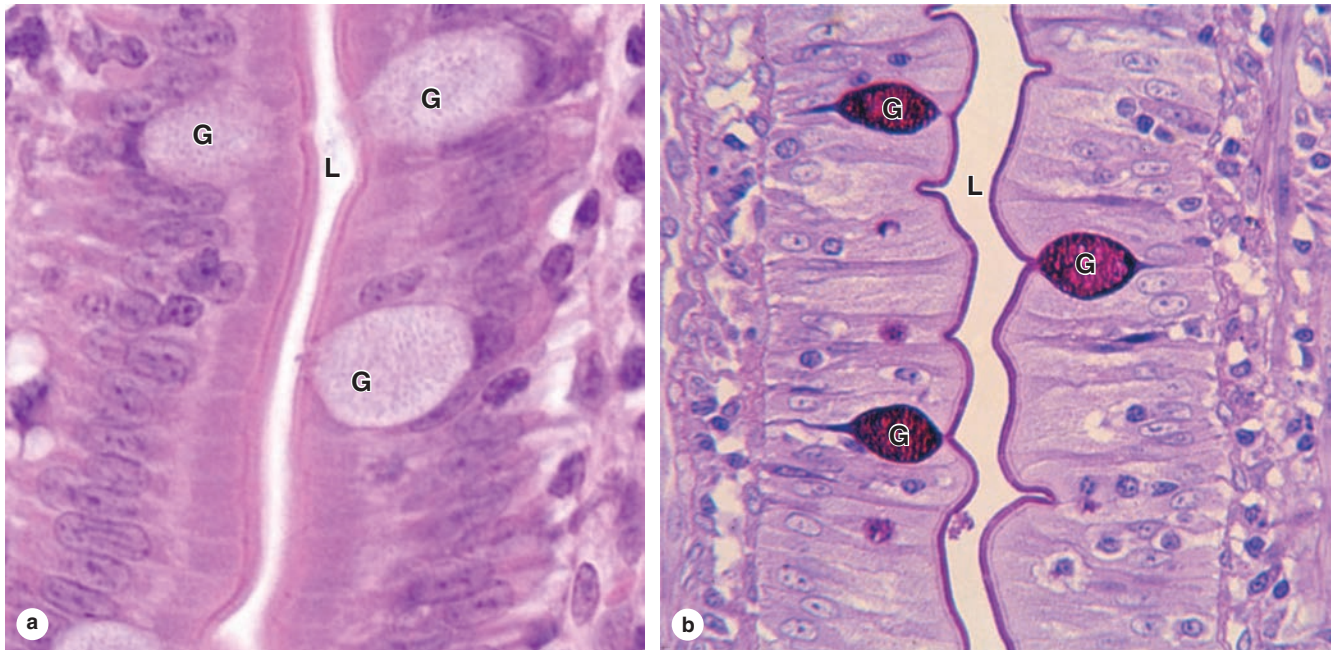
Examples of basic dyes include toluidine blue, alcian blue, and methylene blue. Hematoxylin behaves like a basic dye, staining basophilic tissue components. The main tissue components that ionize and react with basic dyes do so because of acids in their composition (DNA, RNA, and glycosaminoglycans). Acid dyes (eg, eosin, orange G, and acid fuchsin) stain the acidophilic components of tissues such as mitochondria, secretory granules, and collagen.

Of all staining methods, the simple combination of **hematoxylin and eosin (H&E)** is used most commonly. Hematoxylin stains DNA in the cell nucleus, RNA-rich portions of the cytoplasm, and the matrix of cartilage, producing a dark blue or purple color. In contrast, eosin stains other cytoplasmic structures and collagen pink (Figure 1–2a). Here eosin is considered a **counterstain**, which is usually a single dye applied separately to distinguish additional features of a tissue. More complex procedures, such as trichrome stains (eg, Masson trichrome), allow greater distinctions among various extracellular tissue components.

The **periodic acid-Schiff (PAS) reaction** utilizes the hexose rings of polysaccharides and other carbohydrate-rich tissue structures and stains such macromolecules distinctly purple or magenta. Figure 1–2b shows an example of cells with carbohydrate-rich areas well-stained by the PAS reaction. The DNA of cell nuclei can be specifically stained using a modification of the PAS procedure called the Feulgen reaction.

Basophilic or PAS-positive material can be further identified by enzyme digestion, pretreatment of a tissue section with an enzyme that specifically digests one substrate. For example, pretreatment with ribonuclease will greatly reduce cytoplasmic basophilia with little overall effect on the nucleus, indicating the importance of RNA for the cytoplasmic staining.

Lipid-rich structures of cells are revealed by avoiding the processing steps that remove lipids, such as treatment with heat and organic solvents, and staining with **lipid-soluble dyes** such as **Sudan black**, which can be useful in diagnosis of metabolic diseases that involve intracellular accumulations of cholesterol, phospholipids, or glycolipids. Less common methods of staining can employ **metal impregnation** techniques, typically using solutions of silver salts to visualize certain ECM fibers and specific cellular elements in nervous tissue. The Appendix lists important staining procedures used for most of the light micrographs in this book.

**FIGURE 1–2 Hematoxylin and eosin (H&E) and periodic acid–Schiff (PAS) staining.**

Micrographs of epithelium lining the small intestine, **(a)** stained with H&E, and **(b)** stained with the PAS reaction for glycoproteins. With H&E, basophilic cell nuclei are stained purple, while cytoplasm stains pink. Cell regions with abundant oligosaccharides on glycoproteins, such as the ends of the cells at the lumen (L) or the scattered mucus-secreting goblet cells (G), are poorly stained. With PAS, however, cell staining is most intense at the

lumen, where projecting microvilli have a prominent layer of glycoproteins at the lumen (L) and in the mucin-rich secretory granules of goblet cells. Cell surface glycoproteins and mucin are PAS-positive because of their high content of oligosaccharides and polysaccharides, respectively. The PAS-stained tissue was counterstained with hematoxylin to show the cell nuclei. (a. X400; b. X300)

Slide preparation, from tissue fixation to observation with a light microscope, may take from 12 hours to 2½ days, depending on the size of the tissue, the embedding medium, and the method of staining. The final step before microscopic observation is mounting a protective glass coverslip on the slide with clear adhesive.

## ▶ LIGHT MICROSCOPY

Conventional bright-field microscopy and more specialized applications like fluorescence, phase-contrast, confocal, and polarizing microscopy are all based on the interaction of light with tissue components and are used to reveal and study tissue features.

### Bright-Field Microscopy

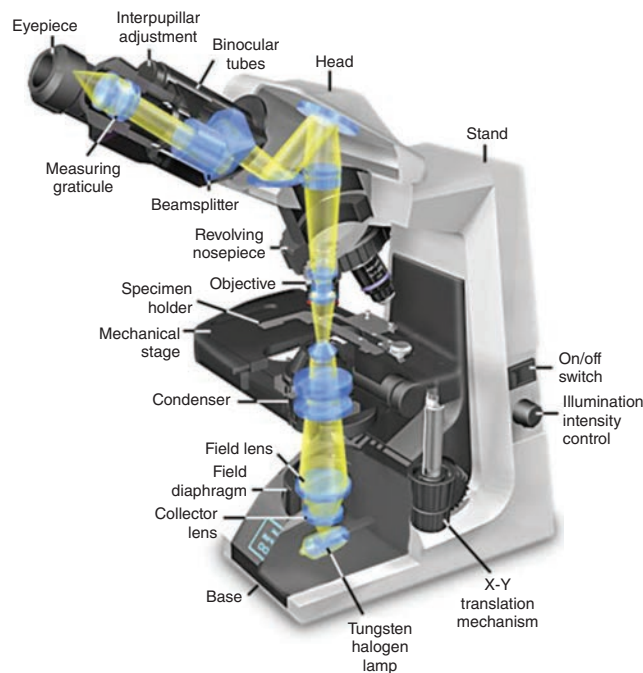
With the **bright-field microscope**, stained tissue is examined with ordinary light passing through the preparation. As shown in Figure 1–3, the microscope includes an optical system and mechanisms to move and focus the specimen. The optical components are the **condenser** focusing light on the object to be studied; the **objective** lens enlarging and projecting the image of the object toward the observer; and the **eyepiece**

(or ocular lens) further magnifying this image and projecting it onto the viewer's retina or a charge-coupled device (CCD) highly sensitive to low light levels with a camera and a monitor. The total magnification is obtained by multiplying the magnifying power of the objective and ocular lenses.

The critical factor in obtaining a crisp, detailed image with a light microscope is its **resolving power**, defined as the smallest distance between two structures at which they can be seen as separate objects. The maximal resolving power of the light microscope is approximately 0.2  $\mu\text{m}$ , which can permit clear images magnified 1000–1500 times. Objects smaller or thinner than 0.2  $\mu\text{m}$  (such as a single ribosome or cytoplasmic microfilament) cannot be distinguished with this instrument. Likewise, two structures such as mitochondria will be seen as only one object if they are separated by less than 0.2  $\mu\text{m}$ . The microscope's resolving power determines the quality of the image, its clarity and richness of detail, and depends mainly on the quality of its objective lens. Magnification is of value only when accompanied by high resolution. Objective lenses providing higher magnification are designed to also have higher resolving power. The eyepiece lens only enlarges the image obtained by the objective and does not improve resolution.

**Virtual microscopy**, typically used for the study of bright-field microscopic preparations, involves the conversion

**FIGURE 1–3** Components and light path of a bright-field microscope.



Photograph of a bright-field light microscope showing its mechanical components and the pathway of light from the substage lamp to the eye of the observer. The optical system has three sets of lenses:

- The **condenser** collects and focuses a cone of light that illuminates the tissue slide on the stage.
- **Objective** lenses enlarge and project the illuminated image of the object toward the eyepiece. Interchangeable objectives with different magnifications routinely used in histology include X4 for observing a large area (field) of the tissue at low magnification; X10 for medium magnification of a smaller field; and X40 for high magnification of more detailed areas.
- The two **eyepieces** or oculars magnify this image another X10 and project it to the viewer, yielding a total magnification of X40, X100, or X400.

of a stained tissue preparation to high-resolution digital images and permits study of tissues using a computer or other digital device, without an actual stained slide or a microscope. In this technique, regions of a glass-mounted specimen are captured digitally in a grid-like pattern at multiple magnifications using a specialized slide-scanning microscope and saved as thousands of consecutive image files. Software then converts this dataset for storage on a server using a format that allows access, visualization, and navigation of the original slide with common web browsers or other devices. With advantages in cost and ease of use, virtual microscopy is rapidly replacing light microscopes and collections of glass slides in histology laboratories for students.

## Fluorescence Microscopy

When certain cellular substances are irradiated by light of a proper wavelength, they emit light with a longer wavelength—a phenomenon called **fluorescence**. In **fluorescence microscopy**, tissue sections are usually irradiated with ultraviolet (UV) light and the emission is in the visible portion of the spectrum. The fluorescent substances appear bright on a dark background. For fluorescent microscopy, the instrument has a source of UV or other light and filters that select rays of different wavelengths emitted by the substances to be visualized.

Fluorescent compounds with affinity for specific cell macromolecules may be used as fluorescent stains. Acridine orange, which binds both DNA and RNA, is an example. When observed in the fluorescence microscope, these nucleic acids emit slightly different fluorescence, allowing them to be localized separately in cells (Figure 1–4a). Other compounds, such as DAPI and Hoechst stain, specifically bind DNA and are used to stain cell nuclei, emitting a characteristic blue fluorescence under UV. Another important application of fluorescence microscopy is achieved by coupling compounds such as fluorescein to molecules that will specifically bind to certain cellular components and thus allow the identification of these structures under the microscope (Figure 1–4b). Antibodies labeled with fluorescent compounds are extremely important in immunohistologic staining. (See the section Visualizing Specific Molecules.)

## Phase-Contrast Microscopy

Unstained cells and tissue sections, which are usually transparent and colorless, can be studied with these modified light microscopes. Cellular detail is normally difficult to see in unstained tissues because all parts of the specimen have roughly similar optical densities. **Phase-contrast microscopy**, however, uses a lens system that produces visible images from transparent objects and, importantly, can be used with living, cultured cells (Figure 1–5).

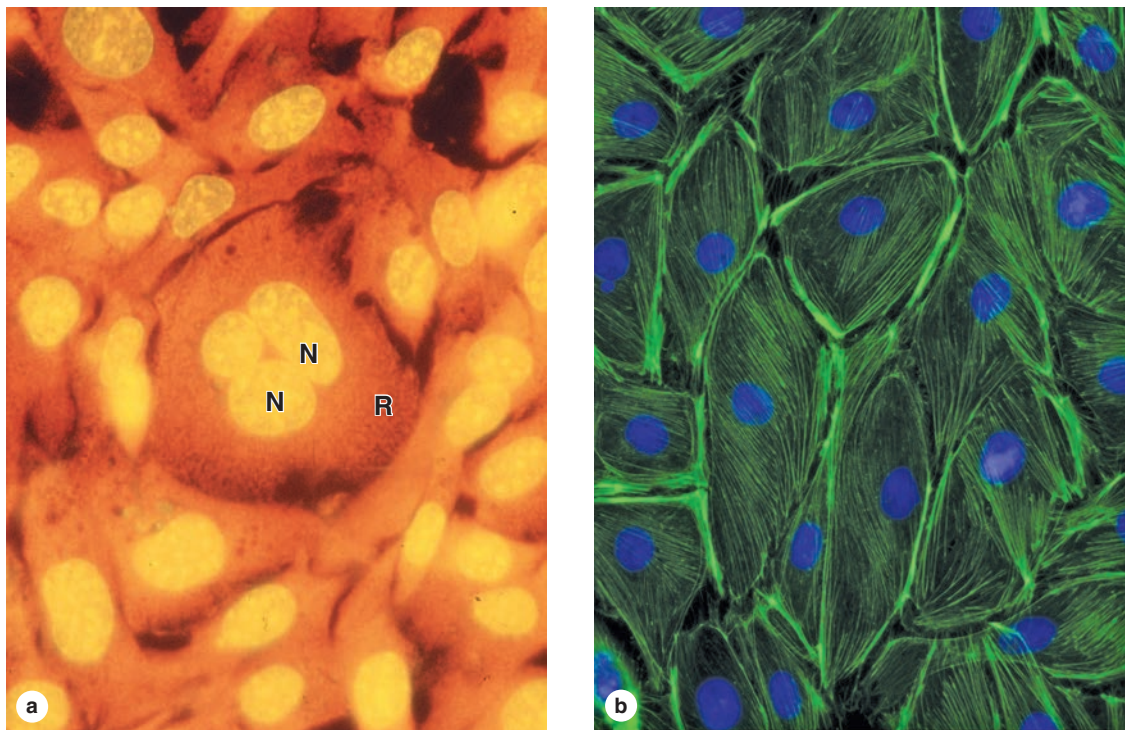
Phase-contrast microscopy is based on the principle that light changes its speed when passing through cellular and extracellular structures with different refractive indices. These changes are used by the phase-contrast system to cause the structures to appear lighter or darker in relation to each other. Because they allow the examination of cells without fixation or staining, phase-contrast microscopes are prominent tools in all cell culture laboratories. A modification of phase-contrast microscopy is **differential interference contrast microscopy** with Nomarski optics, which produces an image of living cells with a more apparent three-dimensional (3D) aspect (Figure 1–5c).

## Confocal Microscopy

With a regular bright-field microscope, the beam of light is relatively large and fills the specimen. Stray (excess) light reduces contrast within the image and compromises the



FIGURE 1–4 Appearance of cells with fluorescent microscopy.



Components of cells are often stained with compounds visible by fluorescence microscopy.

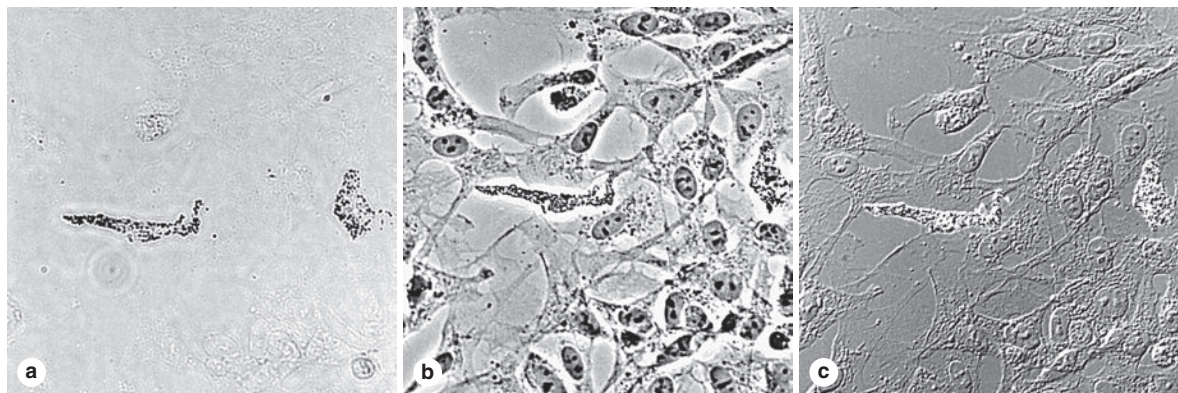
**(a)** Acridine orange binds nucleic acids and causes DNA in cell nuclei (**N**) to emit yellow light and the RNA-rich cytoplasm (**R**) to appear orange in these cells of a kidney tubule.

**(b)** Cultured cells stained with DAPI (4',6-diamino-2-phenylindole) that binds DNA and with fluorescein phalloidin that binds actin

filaments show nuclei with blue fluorescence and actin filaments stained green. Important information such as the greater density of microfilaments at the cell periphery is readily apparent. (Both  $\times 500$ )

(Figure 1–4b, used with permission from Drs Claire E. Walczak and Rania Rizk, Indiana University School of Medicine, Bloomington.)

FIGURE 1–5 Unstained cells' appearance in three types of light microscopy.



Living neural crest cells growing in culture appear differently with various techniques of light microscopy. Here the *same field* of unstained cells, including two differentiating pigment cells, is shown using three different methods (all  $\times 200$ ):

**(a) Bright-field microscopy:** Without fixation and staining, only the two pigment cells can be seen.

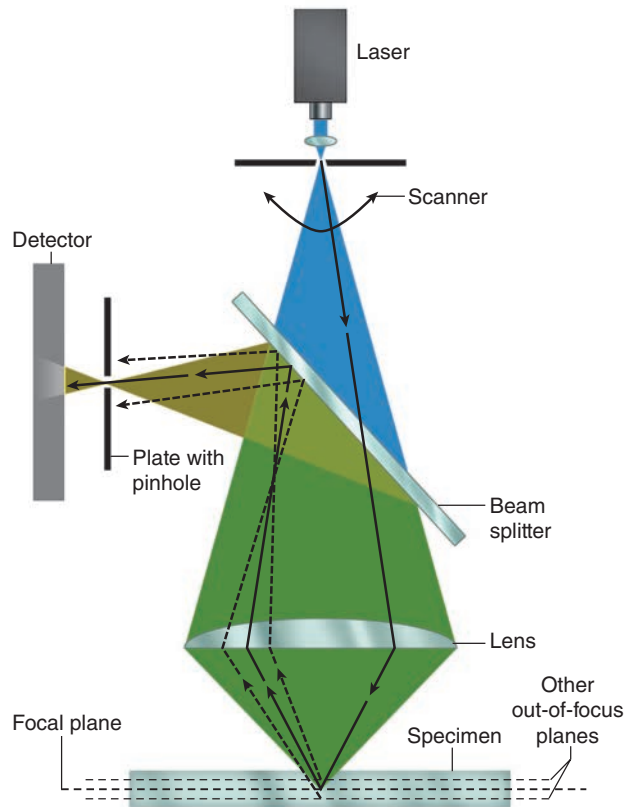
**(b) Phase-contrast microscopy:** Cell boundaries, nuclei, and cytoplasmic structures with different refractive indices affect

in-phase light differently and produce an image of these features in *all* the cells.

**(c) Differential interference contrast microscopy:** Cellular details are highlighted in a different manner using Nomarski optics. Phase-contrast microscopy, with or without differential interference, is widely used to observe live cells grown in tissue culture.

(Used with permission from Dr Sherry Rogers, Department of Cell Biology and Physiology, University of New Mexico, Albuquerque, NM.)

**FIGURE 1–6 Principle of confocal microscopy.**



Although a very small spot of light originating from one plane of the section crosses the pinhole and reaches the detector, rays originating from other planes are blocked by the blind. Thus, only one very thin plane of the specimen is focused at a time. The diagram shows the practical arrangement of a confocal microscope. Light from a laser source hits the specimen and is reflected. A beam splitter directs the reflected light to a pinhole and a detector. Light from components of the specimen that are above or below the focused plane is blocked by the blind. The laser scans the specimen so that a larger area of the specimen can be observed.

resolving power of the objective lens. Confocal microscopy (Figure 1–6) avoids these problems and achieves high resolution and sharp focus by using (1) a small point of high-intensity light, often from a laser and (2) a plate with a pinhole aperture in front of the image detector. The point light source, the focal point of the lens, and the detector's pinpoint aperture are all optically conjugated or aligned to each other in the focal plane (confocal), and unfocused light does not pass through the pinhole. This greatly improves resolution of the object in focus and allows the localization of specimen components with much greater precision than with the bright-field microscope.

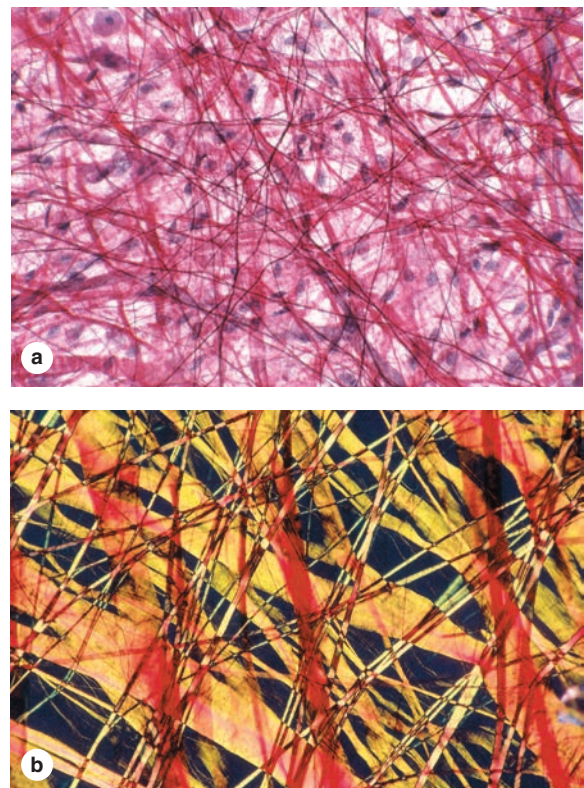
Confocal microscopes include a computer-driven mirror system (the beam splitter) to move the point of illumination across the specimen automatically and rapidly. Digital images captured at many individual spots in a very thin plane of focus are used to produce an “optical section” of that plane. Creating

such optical sections at a series of focal planes through the specimen allows them to be digitally reconstructed into a 3D image.

## Polarizing Microscopy

Polarizing microscopy allows the recognition of stained or unstained structures made of highly organized subunits. When normal light passes through a **polarizing** filter, it exits vibrating in only one direction. If a second filter is placed in the microscope above the first one, with its main axis perpendicular to the first filter, no light passes through. If, however, tissue structures containing oriented macromolecules are located between the two polarizing filters, their repetitive structure rotates the axis of the light emerging from the polarizer and they appear as bright structures against a dark background (Figure 1–7). The ability to rotate the direction of vibration of polarized light is called **birefringence** and is

**FIGURE 1–7 Tissue appearance with bright-field and polarizing microscopy.**



Polarizing light microscopy produces an image only of material having repetitive, periodic macromolecular structure; features without such structure are not seen. Pieces of thin, unsectioned mesentery were stained with red picosirius, orcein, and hematoxylin, placed on slides and observed by bright-field (**a**) and polarizing (**b**) microscopy.

**(a)** With bright-field microscopy, collagen fibers appear red, with thin elastic fibers and cell nuclei darker. (X40)

**(b)** With polarizing microscopy, only the collagen fibers are visible and exhibit intense yellow or orange birefringence. (a: X40; b: X100)

a feature of crystalline substances or substances containing highly oriented molecules, such as cellulose, collagen, microtubules, and actin filaments.

The utility of all light microscopic methods is greatly extended through the use of digital cameras. Many features of digitized histologic images can be analyzed quantitatively using appropriate software. Such images can also be enhanced to allow objects not directly visible through the eyepieces to be examined on a monitor.

## ▶ ELECTRON MICROSCOPY

Transmission and scanning electron microscopes are based on the interaction of tissue components with beams of electrons.

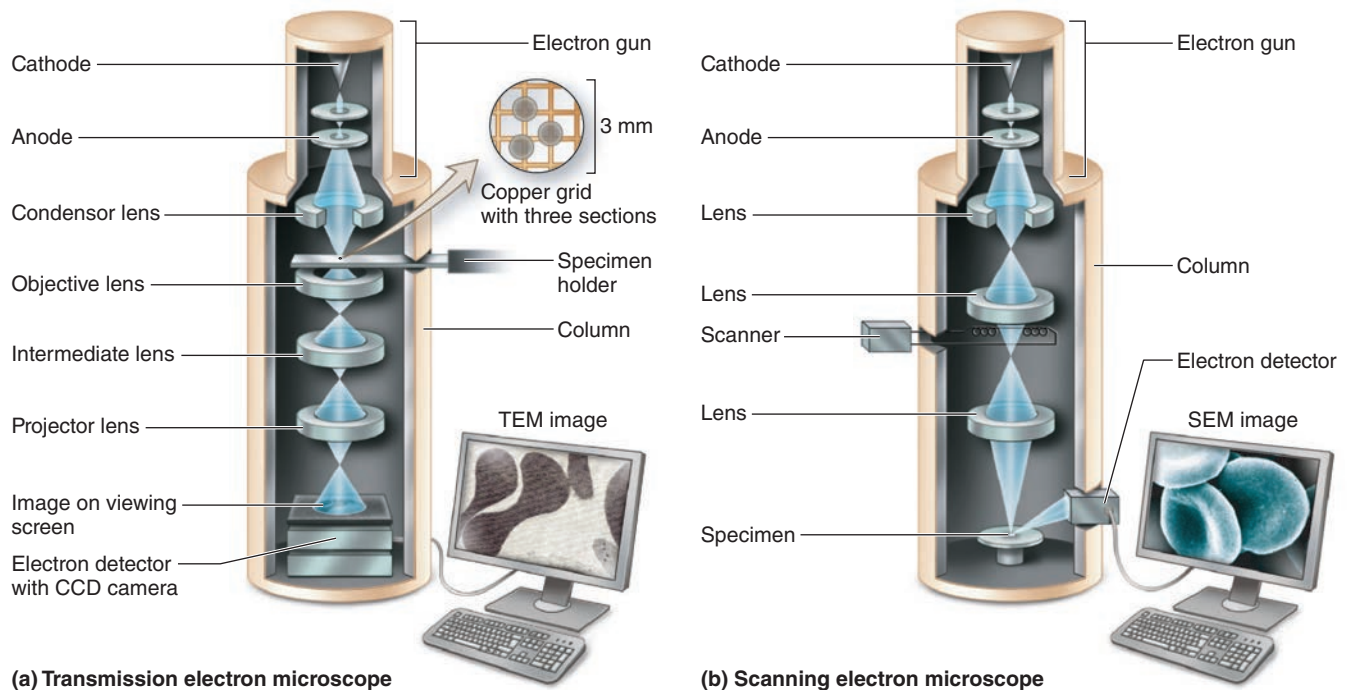
The wavelength in an electron beam is much shorter than that of light, allowing a 1000-fold increase in resolution.

### Transmission Electron Microscopy

The **transmission electron microscope (TEM)** is an imaging system that permits resolution around 3 nm. This high resolution allows isolated particles magnified as much as 400,000 times to be viewed in detail. Very thin (40–90 nm), resin-embedded tissue sections are typically studied by TEM at magnifications up to approximately 120,000 times.

Figure 1–8a indicates the components of a TEM and the basic principles of its operation: a beam of electrons focused using electromagnetic “lenses” passes through the tissue section to produce an image with black, white, and intermediate

**FIGURE 1–8** Electron microscopes.



**(a) Transmission electron microscope**

**(b) Scanning electron microscope**

Electron microscopes are large instruments generally housed in a specialized EM facility.

**(a)** Schematic view of the major components of a transmission electron microscope (TEM), which is configured rather like an upside-down light microscope. With the microscope column in a vacuum, a metallic (usually tungsten) filament (cathode) at the top emits electrons that travel to an anode with an accelerating voltage between 60 and 120 kV. Electrons passing through a hole in the anode form a beam that is **focused electromagnetically** by circular electric coils in a manner analogous to the effect of optical lenses on light.

The first lens is a condenser focusing the beam on the section. Some electrons interact with atoms in the section, being absorbed or scattered to different extents, while others are simply transmitted through the specimen with no interaction. Electrons reaching the objective lens form an image that is then magnified and finally projected on a fluorescent screen or a charge-coupled device (CCD) monitor and camera.

In a TEM image, areas of the specimen through which electrons passed appear bright (electron lucent), while denser areas or those that bind heavy metal ions during specimen preparation absorb or deflect electrons and appear darker (electron dense). Such images are therefore always black, white, and shades of gray.

**(b)** The scanning electron microscope (SEM) has many similarities to a TEM. However, here the focused electron beam does not pass through the specimen, but rather is moved sequentially (scanned) from point to point across its surface similar to the way an electron beam is scanned across a television tube or screen. For SEM, specimens are coated with metal atoms with which the electron beam interacts, producing reflected electrons and newly emitted secondary electrons. All of these are captured by a detector and transmitted to amplifiers and processed to produce a black-and-white image on the monitor. The SEM shows only surface views of the coated specimen but with a striking 3D, shadowed quality. The inside of organs or cells can be analyzed after sectioning to expose their internal surfaces.

shades of gray regions. These regions of an electron micrograph correspond to tissue areas through which electrons passed readily (appearing brighter or electron-lucent) and areas where electrons were absorbed or deflected (appearing darker or more electron-dense). To improve contrast and resolution in TEM, compounds with **heavy metal ions** are often added to the fixative or dehydrating solutions used for tissue preparation. These include osmium tetroxide, lead citrate, and uranyl compounds, which bind cellular macromolecules, increasing their electron density and visibility.

**Cryofracture** and **freeze etching** are techniques that allow TEM study of cells without fixation or embedding and have been particularly useful in the study of membrane structure. In these methods, very small tissue specimens are rapidly frozen in liquid nitrogen and then cut or fractured with a knife. A replica of the frozen exposed surface is produced in a vacuum by applying thin coats of vaporized platinum or other metal atoms. After removal of the organic material, the replica of the cut surface can be examined by TEM. With membranes, the random fracture planes often split the lipid bilayers, exposing protein components whose size, shape, and distribution are difficult to study by other methods.

## Scanning Electron Microscopy

**Scanning electron microscopy (SEM)** provides a high-resolution view of the surfaces of cells, tissues, and organs. Like the TEM, this microscope produces and focuses a very narrow beam of electrons, but in this instrument, the beam does not pass through the specimen (Figure 1–8b). Instead, the surface of the specimen is first dried and spray-coated with a very

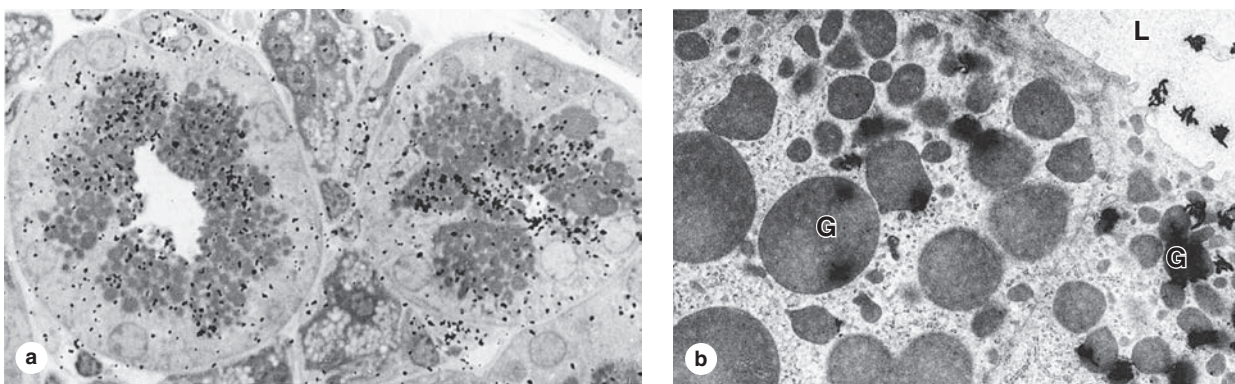
thin layer of heavy metal (often gold) that reflects electrons in a beam scanning the specimen. The reflected electrons are captured by a detector, producing signals that are processed to produce a black-and-white image. SEM images are usually easy to interpret because they present a three-dimensional view that appears to be illuminated in the same way that large objects are seen with highlights and shadows caused by light.

## › AUTORADIOGRAPHY

Microscopic **autoradiography** is a method of localizing newly synthesized macromolecules in cells or tissue sections. Radioactively labeled metabolites (nucleotides, amino acids, sugars) provided to living cells or experimental animals are incorporated into specific macromolecules (DNA, RNA, protein, glycoproteins, and polysaccharides). After tissue fixation, processing, and sectioning only the new, labeled macromolecules continue to emit weak and localized radiation, unincorporated isotope having been washed out during the processing steps. Slides or TEM grids with radiolabeled cells or tissue sections are coated in a darkroom with photographic emulsion in which silver bromide crystals act as microdetectors of the radiation in the same way that they respond to light in photographic film. After an adequate exposure time in lightproof boxes, the slides are developed photographically. Silver bromide crystals reduced by the radiation produce small black grains of metallic silver, which under either the light microscope or TEM indicate the locations of radiolabeled macromolecules in the tissue (Figure 1–9).

Much histological information becomes available by autoradiography. If a radioactive precursor of DNA (such

**FIGURE 1–9** Microscopic autoradiography.



Autoradiographs are tissue preparations in which particles called **silver grains** indicate the cells or regions of cells in which specific macromolecules were synthesized just prior to fixation. Shown here are autoradiographs from the salivary gland of a mouse injected with  $^3\text{H}$ -fucose 8 hours before tissue fixation. Fucose was incorporated into oligosaccharides, and the free  $^3\text{H}$ -fucose was removed during fixation and sectioning of the gland. Autoradiographic processing and microscopy reveal locations of newly synthesized glycoproteins containing that sugar.

**(a)** Black grains of silver from the light-sensitive material coating the specimen are visible over cell regions with secretory granules and the duct indicating glycoprotein locations. (X1500)

**(b)** The same tissue prepared for TEM autoradiography shows silver grains with a coiled or amorphous appearance again localized mainly over the granules (**G**) and in the gland lumen (**L**). (X7500)

(Figure 1–9b, used with permission from Drs Ticiano G. Lima and A. Antonio Haddad, School of Medicine, Ribeirão Preto, Brazil.)